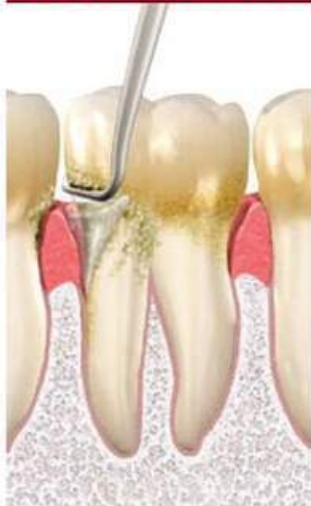

**Periodontal and Oral Mucosa  
Diseases: in 2 volumes. —  
Volume 2: textbook (IV a. I.)**

The textbook presents the part of therapeutic stomatology which deals with problems of etiology, pathogenesis, clinical course, diagnosis, treatment, prevention and general questions of periodontal and oral mucosa diseases. The textbook deals with issues of anatomy and physiology of the periodontium and oral mucosa, clinical features, diagnosis, treatment and prevention of periodontal and oral mucosa diseases. Special attention is given to medicamental, surgical treatment (curettage, gingivectomy, flap operations etc.), physiotherapy (electrotherapy, ultrasound therapy, vacuum therapy, massage and so on). A separate chapter describes methods of examination of the patient. Self-control tests with answer keys are given for knowledge assessment. Textbook is established in accordance with the approved educational program and curriculum in therapeutic dentistry for students of higher education establishments. The textbook is intended for students of dental faculty of higher medical education establishments, interns, dentists.

# Periodontal and Oral Mucosa Diseases

IN 2 VOLUMES



Edited by  
Professor **A.V. BORYSENKO**

RECOMMENDED  
by the Ministry of Health of Ukraine  
as a textbook for students of higher  
medical education establishments

VOLUME **2**

Kyiv  
AUS Medicine Publishing  
2018

UDC 616.31  
LBC 56.6ya73  
P26

*Recommended by the Ministry of Health of Ukraine  
as a textbook for students of higher medical education establishments  
(letter No. 23-01-025/173, 26 October 2007)*

**Authors:**

A.V. Borysenko, L.V. Lynovytska, O.F. Nesyn, Yu.H. Kolenko, Zh.I. Rakhniy,  
L.F. Sidelnikova, I.H. Dikova, A.G. Dimitrova

**Editor:** Professor A.V. Borysenko

**Reviewers:**

*T.O. Petrushanko* — MD, Professor, Head of the Department of Therapeutic Stomatology of Higher State Education Establishment of Ukraine “Ukrainian Medical Stomatological Academy”;

*Ye.M. Riabokon* — MD, Professor, Head of the Department of Therapeutic Stomatology of Kharkiv National Medical University

**Periodontal and Oral Mucosa Diseases** : textbook. Vol. 2 / A.V. Borysenko,  
P26 L.V. Lynovytska, O.F. Nesyn et al. ; edited by A.V. Borysenko. — Kyiv : AUS  
Medicine Publishing, 2018. — 624 p. ; color edition.  
ISBN 978-617-505-673-8

The textbook presents the part of therapeutic stomatology which deals with problems of etiology, pathogenesis, clinical course, diagnosis, treatment, prevention and general questions of periodontal and oral mucosa diseases.

The textbook deals with issues of anatomy and physiology of the periodontium and oral mucosa, clinical features, diagnosis, treatment and prevention of periodontal and oral mucosa diseases. Special attention is given to medicamental, surgical treatment (curettage, gingivectomy, flap operations etc.), physiotherapy (electrotherapy, ultrasound therapy, vacuum therapy, massage and so on). A separate chapter describes methods of examination of the patient.

Self-control tests with answer keys are given for knowledge assessment.

Textbook is established in accordance with the approved educational program and curriculum in therapeutic dentistry for students of higher education establishments.

The textbook is intended for students of dental faculty of higher medical education establishments, interns, dentists.

**UDC 616.31**  
**LBC 56.6ya73**

ISBN 978-617-505-673-8

© A.V. Borysenko, L.V. Lynovytska,  
O.F. Nesyn, Yu.H. Kolenko,  
Zh.I. Rakhniy, L.F. Sidelnikova,  
I.H. Dikova, A.G. Dimitrova, 2018  
© AUS Medicine Publishing, design, 2018

# Contents

---

<b>ABBREVIATIONS .....</b>	<b>7</b>
----------------------------	----------

## PART I PERIODONTAL DISEASES

Introduction .....	9
<b>CHAPTER 1. ANATOMIC AND HISTOLOGIC STRUCTURE OF THE PERIODONTIUM .....</b>	<b>10</b>
Normal Periodontium .....	10
Innervation of the Periodontium.....	20
The Functions of the Periodontium.....	21
Effects of Aging on the Periodontium.....	22
<b>CHAPTER 2. EXAMINATION OF PATIENTS WITH PERIODONTAL DISEASES .....</b>	<b>25</b>
Clinical diagnosis .....	25
Anamnesis .....	25
Oral Examination.....	27
Use of Clinical Indices in Dental Practice.....	58
Labouratory Methods for Periodontal Diseases Diagnostics .....	65
<b>CHAPTER 3. CLASSIFICATION OF PERIODONTAL DISEASES .....</b>	<b>71</b>
Gingival diseases .....	72
Periodontitis.....	78
Developmental or acquired deformities and conditions .....	83
Classifications of periodontal diseases in Russia and Ukraine.....	85
<b>CHAPTER 4. AETIOLOGY OF PERIODONTAL DISEASES .....</b>	<b>88</b>
Local factors.....	88
Systemic factors.....	105
<b>CHAPTER 5. INFLAMMATORY PERIODONTAL DISEASES .....</b>	<b>123</b>
Gingival Inflammation Gingivitis.....	123
Classification .....	153
<b>CHAPTER 6. DYSTROPHIC INFLAMMATORY PERIODONTAL DISEASES .....</b>	<b>164</b>
Chronic Periodontitis (Generalised Periodontitis) .....	164
Periodontosis .....	192
<b>CHAPTER 7. PROGRESSIVE IDIOPATHIC DISEASES .....</b>	<b>198</b>
Periodontal Manifestations Accompanying Blood Diseases .....	198
Periodontal Manifestations Accompanying Langerhans Cell Disease .....	205
Periodontal Manifestations Accompanying Metabolic Disorders .....	209
Periodontal Manifestations Accompanying Immunodeficiency Disorders .....	212
Periodontal Manifestations Accompanying Congenital Disorders.....	218

**CONTENTS**

Neoplasms of Periodontal Tissues .....	219
Malignant Tumours of the Gingiva .....	222
<b>CHAPTER 8. TREATMENT OF PERIODONTAL DISEASES .....</b>	<b>224</b>
Periodontal Treatment Planning .....	224
Phase I. Periodontal Therapy .....	225
Phase II. Periodontal Therapy .....	257
Classification Of Flaps .....	270
Physiotherapy of Periodontal Diseases .....	285
Prosthetic (Orthopaedic) Treatment.....	292
Systemic Treatment.....	295
<b>CHAPTER 9. MAINTENANCE OF PATIENTS WITH PERIODONTAL DISEASES .....</b>	<b>298</b>
Maintenance Therapy (Recall). Phase 4 Therapy .....	298
<b>CHAPTER 10. PERIODONTAL DISEASE TESTS.....</b>	<b>314</b>
Periodontal Disease Diagnostics.....	314
Gingivitis.....	319
Generalised Periodontitis .....	321
Periodontosis.....	325
Treatment of Periodontal Diseases.....	328
<b>SELECTED READING.....</b>	<b>333</b>

**PART II**  
**ORAL MUCOSA DISEASES**

Introduction .....	334
<b>CHAPTER 11. ANATOMIC AND HISTOLOGIC STRUCTURE OF THE ORAL MUCOSA.....</b>	<b>335</b>
Anatomic Structure of Oral Mucosa .....	335
Histologic Structure of Oral Mucosa.....	338
Specific Histological Features of Different Regions of the Oral Mucosa .....	342
Nerves and Blood Supply.....	346
Oral Mucosa Functions.....	347
Changes with Aging.....	347
<b>CHAPTER 12. PRINCIPLES OF EXAMINATION OF PATIENTS WITH ORAL MUCOSA DISEASES .....</b>	<b>349</b>
Anamnesis .....	349
Objective Findings and Procedures During Oral Cavity Examination.....	353
Elements of Oral Mucosa Lesions.....	356
Medical Examination .....	368
Additional Diagnostic Methods.....	368
Special Investigations .....	369
Additional Laboratory Tests .....	370
Making a Clinical Differential Diagnosis and Investigation Plan.....	373
<b>CHAPTER 13. CLASSIFICATION OF ORAL MUCOSA LESIONS.....</b>	<b>375</b>
<b>CHAPTER 14. TRAUMATIC LESIONS OF THE ORAL MUCOSA. LEUCOPLAKIA .....</b>	<b>377</b>
Mechanical Trauma .....	377
Physical Trauma.....	383
Chemical Trauma.....	384
Leucoplakia .....	386

<b>CHAPTER 15. INFECTIOUS ORAL MUCOSA LESIONS .....</b>	<b>394</b>
Virus Infections .....	394
Bacterial Infections .....	420
Fungal Infections .....	427
Specific Bacterial Lesions.....	434
<b>CHAPTER 16. CHEILITIS.....</b>	<b>452</b>
Artificial Cheilitis .....	452
Infectious Cheilitis .....	454
Allergic Cheilitis.....	456
Cheilitis with Destructive Changes in Epithelium.....	460
Cheilitis as a Result of Minor Salivary Gland Inflammation .....	462
Macrocheilia .....	463
<b>CHAPTER 17. TONGUE DISEASES .....</b>	<b>468</b>
Geographic Tongue.....	468
Hairy Tongue (Black Hairy Tongue) .....	470
Median Rhomboid Glossitis.....	472
Fissured Tongue (Lingua Plicata) .....	473
<b>CHAPTER 18. ORAL PREMALIGNANCIES .....</b>	<b>475</b>
Oral Premalignancies.....	475
Cheilitis Abrasiva Praecancerosa Manganotti.....	478
Bowen's disease.....	479
Praecancer Verrucosus .....	480
Limited Precancerous Hyperkeratosis of the Vermilion Border .....	480
Erythroplasia of Queyrat .....	481
Cutaneous horn.....	481
Keratoacanthoma .....	482
Papilloma .....	483
Cancer of the Oral Mucosa and Vermilion Border .....	483
<b>CHAPTER 19. ALLERGIC LESIONS OF THE ORAL MUCOSA.....</b>	<b>487</b>
Generalised Anaphylaxis .....	487
Localised Anaphylaxis .....	489
Angiooedema.....	489
Contact Allergic Stomatitis .....	491
Recurring Oral Ulcers .....	493
Erythema multiforme .....	497
Stevens–Johnson Syndrome.....	500
<b>CHAPTER 20. ORAL LESIONS IN AUTOIMMUNE DERMATOLOGIC DISEASES.....</b>	<b>502</b>
Pemphigus.....	502
Subepithelial Bullous Dermatoses (Pemphigoids) .....	504
Oral Lichen Planus .....	507
<b>CHAPTER 21. ORAL MUCOSA LESIONS IN EXOGENIC INTOXICATION.....</b>	<b>513</b>
Mercurial Stomatitis.....	513
Lead Stomatitis .....	514
Bismuth Stomatitis.....	515
Oral Mucosa Lesions in Radiation Sickness.....	516

## CONTENTS

---

<b>CHAPTER 22. SYSTEMIC LESIONS OF ORAL MUCOSA (SYMPTOMATIC)</b> .....	<b>520</b>
Mucous Membrane Findings in Gastrointestinal Diseases .....	520
Mucous Membrane Findings in Cardiovascular Disease .....	526
Mucous Membrane Findings in Haematologic Diseases .....	528
Red Blood Cell Disorders .....	529
White Blood Cell Disorders .....	532
Bleeding and Clotting Disorders .....	541
Endocrine Diseases .....	546
Vitamin Deficiency .....	553
Connective-Tissue Diseases .....	562
<b>CHAPTER 23. NEUROSTOMATOLOGY DISEASES</b> .....	<b>567</b>
Trigeminal Neuralgia .....	567
Vegetative Ganglionitis .....	568
Ganglionitis Pterigopalatinus .....	569
<b>CHAPTER 24. ORAL MUCOSA DISEASES TESTS</b> .....	<b>573</b>
<b>SELECTED READING</b> .....	<b>623</b>



## Part I

---

# PERIODONTAL DISEASES

### INTRODUCTION

Over the past century periodontal disease incidence has increased. Periodontal disease promotes the development of oral sepsis, which precipitates a number of systemic diseases.

Periodontal disease is accompanied by more complex and profound metabolic, endocrinological and immunological changes. As a result different morphological changes develop in the periodontal tissues. Timely comprehensive treatment is of great importance. Dentists should be able to diagnose periodontal disease.

The appearance and further development of many periodontal diseases (gingivitis, generalised periodontitis) are very slow. Often patients do not pay much attention to the first signs of the disease, such as bleeding and slight swelling of the gums. Treatment should be comprehensive and include many therapeutic, orthopaedic, surgical and physiotherapeutic techniques. The maintenance therapy of the patient is mandatory.

All of this highlights the need for careful study of periodontal disease. The organisation of medical care for patients with periodontal disease requires considerable improvement. This part of textbook is devoted to these important problems.

## Chapter 1

# ANATOMIC AND HISTOLOGIC STRUCTURE OF THE PERIODONTIUM

### NORMAL PERIODONTIUM

**Periodontology** is the study of the tooth-supporting tissues, the periodontium. The periodontium is made up of those tissues that surround each tooth and which anchor each tooth into the alveolar process (Latin: *para* = adjacent to; Greek: *odontos* = tooth). The main function of the periodontium is to attach the tooth to the bone tissue of the jaws and to maintain the integrity of the surface of the masticatory mucosa of the oral cavity. The periodontium, also called *the attachment apparatus* or *the supporting tissues of the teeth*, constitutes a developmental, biologic and functional unit, which undergoes certain changes with age and is, in addition, subjected to morphologic changes related to functional alterations and alterations in the oral environment (Fig. 1).

The periodontium consists of the investing and supporting tissues of the tooth (gingiva, periodontal ligament, cementum, alveolar bone). The cementum is considered a part of the periodontium because, along with the bone, it serves as the support for the fibres of the periodontal ligament. The periodontium is subject to morphologic and functional variations, as well as changes associated with age.

The development of the periodontal tissues occurs during the development and formation of teeth and ends after eruption of the last tooth in dentition.

### Gingiva

The oral mucosa (mucous membrane) is continuous with the skin of the lips and the mucosa of the soft palate and pharynx. The oral mucosa consists of (1) the masticatory mucosa, which includes the gingiva and the covering of the hard palate, (2) the specialised mucosa, which covers the dorsum of the tongue and (3) the remaining part called the lining mucosa. The gingiva is the part of the oral mucosa that covers the alveolar processes of the jaws and surrounds the necks of the teeth.

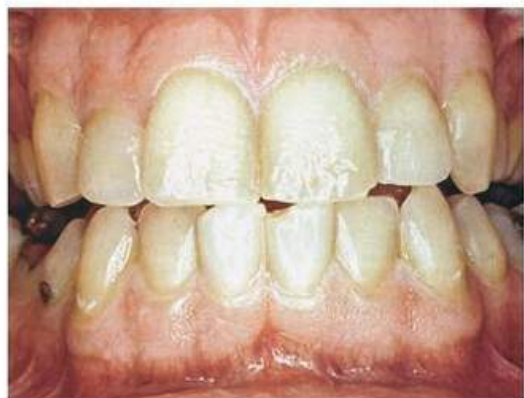

Fig. 1. Normal periodontium

The gingiva is divided anatomically into *marginal*, *attached* and *interdental areas* (Fig. 2). Although each type of gingiva exhibits considerable variation in differentiation, histology and thickness according to its functional demands, all types

are specifically structured to function appropriately against mechanical and microbial damage. That is, the specific structure of different types of gingiva reflects its effectiveness as a barrier to the penetration of microbes and noxious agents into the deeper tissue.

In the coronal direction the coral pink gingiva terminates in the free gingival margin, which has a scalloped outline. In the apical direction the gingiva is continuous with the loose, darker red alveolar mucosa (lining mucosa), from which the gingiva is separated by a, usually, easily recognisable borderline called either the mucogingival junction or the mucogingival line.

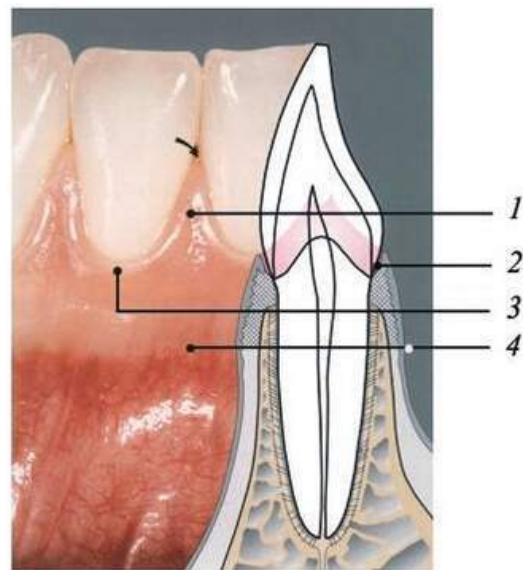
The free gingiva is coral pink, has a dull surface and firm consistency. It comprises the gingival tissue at the vestibular and lingual/palatal aspects of the teeth and the interdental gingiva or the interdental papillae. On the vestibular and lingual sides of the teeth, the free gingiva extends from the gingival margin in apical direction to the free gingival groove, which is positioned at a level corresponding to the level of the cemento-enamel junction (CEJ). The attached gingiva is in apical direction demarcated by the mucogingival junction (MGJ).

After completed tooth eruption, the free gingival margin is located on the enamel surface approximately 1.5 to 2 mm coronal to the cemento-enamel junction. In the anterior regions of the dentition, the interdental papilla is of pyramidal form while in the molar regions, the papillae are more flattened in the buccolingual direction. Due to the presence of interdental papillae, the free gingival margin follows a more or less accentuated, scalloped course through the dentition.

The free gingival groove is often most pronounced on the vestibular aspect of the teeth, occurring most frequently in the incisor and premolar regions of the mandible and least frequently in the mandibular molar and maxillary premolar regions. The attached gingiva extends in the apical direction to the mucogingival junction (arrows), where it becomes continuous with the alveolar (lining) mucosa (AM). It is of firm texture, coral pink in colour and often shows small depressions on the surface. The depressions, named *stippling*, give the appearance of orange peel. It is firmly attached to the underlying alveolar bone and cementum by connective tissue fibres and is, therefore, comparatively immobile in relation to the underlying tissue. The darker red alveolar mucosa (AM) located apical to the mucogingival junction, on the other hand, is loosely bound to the underlying bone. Therefore, in contrast to the attached gingiva, the alveolar mucosa is mobile in relation to the underlying tissue.

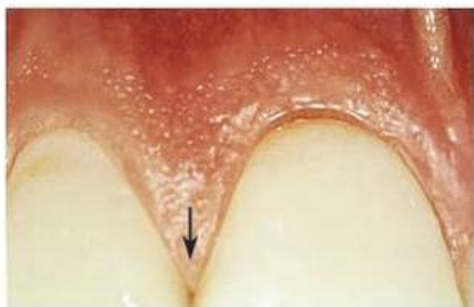In the marginal region, one observes the inflammation-free gingiva, which provides the epithelial attachment to the tooth by means of its junctional epithelium (pink collar). This connection protects the deeper-lying components of the periodontium from mechanical and microbiologic insult (Fig. 3).

Subjacent to the junctional epithelium, one observes the supracrestal fibres, which serve to connect the tooth with the gingiva and also the periodontal ligament fibres in



**Fig. 2.** The gingiva areas:  
1 — interdental; 2 — gingival sulcus;  
3 — marginal; 4 — attached

## PART I. PERIODONTAL DISEASES



**Fig. 3.** Marginal gingiva and interdental papilla

the region of the alveolar bone, which insert into the bone and the cementum of the root surface.

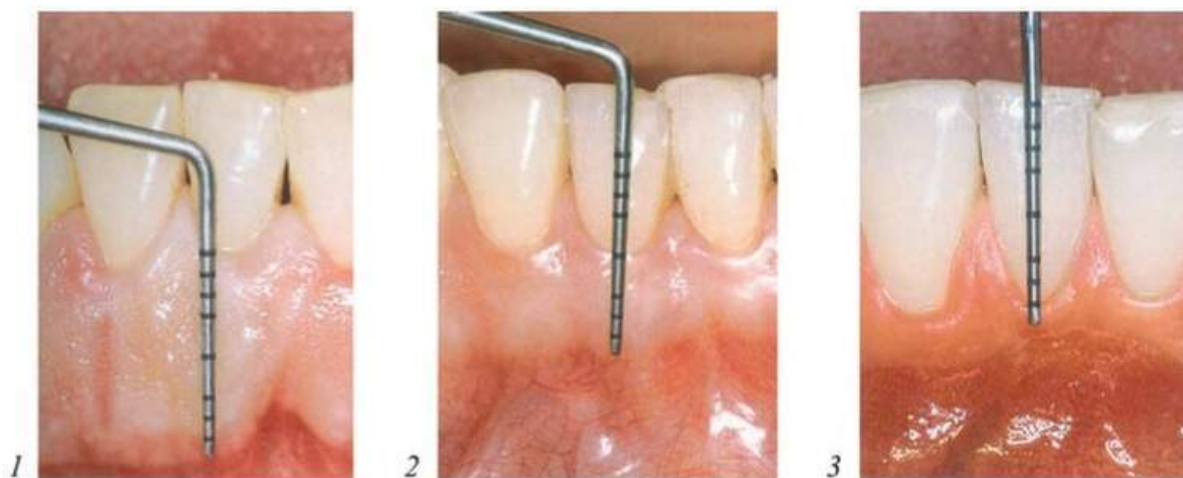
In the *maxilla*, the *facial* gingiva in the area of the incisors is wide, but narrow around the canines and first premolars. On the *palatal* aspect, the marginal gingiva blends without demarcation into the palatal mucosa. In the *mandible*, the *lingual* gingiva in the area of the incisors is narrow, but wide on the molars. On the *facial* aspect, the gingiva around the canines and first premolars is narrow, but wide around the lateral incisors.

The gingiva is one portion of the oral mucosa. It is also the most peripheral component of the periodontium. The gingiva begins at the mucogingival line and covers the coronal aspect of the alveolar process. On the palatal aspect, the mucogingival line is absent; here, the gingiva is a part of the keratinised, non-mobile palatal mucosa. The gingiva ends at the cervix of each tooth, surrounds it and forms there the epithelial attachment by means of a ring of specialised epithelial tissue (junctional epithelium). Thus the gingiva provides for the continuity of the epithelial lining of the oral cavity.

The gingiva is demarcated clinically into the *free marginal* gingiva, ca. 1.5 mm wide; the *attached* gingiva, which may be of varying width; and the *interdental* gingiva. Healthy gingiva is described as “salmon” pink in colour; in Blacks (seldom also in Caucasians) the gingiva may exhibit varying degrees of brownish pigmentation. The gingiva exhibits varying consistency and is not mobile upon the underlying bone. The gingival surface is keratinised and may be firm, thick and deeply stippled (“thick phenotype”), or thin and scarcely stippled (“thin phenotype”).

The attached gingiva becomes wider as a patient ages. The width varies between individuals and among various groups of teeth in the same person. Although it was once believed that a minimum width of the attached gingiva (ca. 2 mm) is necessary to maintain the health of the periodontium (Fig. 4).

Apical to the contact area between two teeth, the interdental gingiva assumes a concave form when viewed in the labio-lingual section. The concavity, the “col”, is thus lo-



**Fig. 4.** The width of the attached gingiva:  
1 — large; 2 — middle; 3 — small

cated between the lingual and facial interdental papillae and is not visible clinically. Depending on the expanse of the contacting tooth surfaces, the col will be of varying depth and breadth. The epithelium covering the col consists of the marginal epithelia of the adjacent teeth.

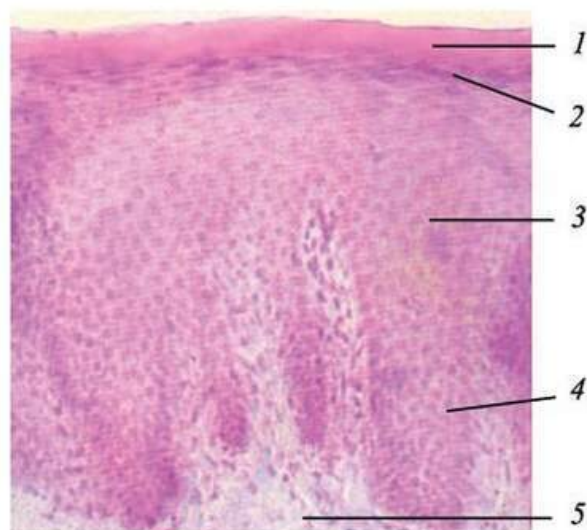
**Gingival Epithelium.** As the tissue that forms the surface of the oral mucosa, the oral epithelium represents the primary barrier between the oral environment and the deeper tissues. It is a stratified squamous epithelium and consists of cells tightly attached to one another and arranged in a number of distinct layers or strata (Fig. 5).

The **basal layer** (frequently given the Latin name *stratum basale*) is a layer of cuboid or columnar cells adjacent to the basement membrane. They are in contact with the basement membrane that separates the epithelium and the connective tissue. The basal cells possess the ability to divide, i. e. undergo mitotic cell division.

Above the basal layer are several rows of larger elliptical or spherical cells known as the **prickle-cell layer** or *stratum spinosum*. This term arises from the appearance of the cells when prepared for histologic examination, since they frequently shrink away from one another, remaining in contact only at points known as the intercellular bridges or desmosomes. The stratum spinosum consists of 10–20 layers of relatively large, polyhedral cells, equipped with short cytoplasmic processes resembling spines. The cytoplasmic processes occur at regular intervals and give the cells a prickly appearance. Together with intercellular protein-carbohydrate complexes, cohesion between the cells is provided by numerous “desmosomes” (pairs of hemidesmosomes), which are located between the cytoplasmic processes of adjacent cells. This alignment gives the cells a spiny or prickle-like profile. It is worth noting that the Greek word for prickle, *acanthē*, is frequently used in pathologic descriptions of an increased thickness (acanthosis) or a separation of cells due to loss of the intercellular bridges (acantholysis) in this layer. The basal and prickle-cell layers together constitute from half to two thirds of the thickness of the epithelium.

The next layer consists of larger flattened cells that contain numbers of small granules that stain intensely with acid dyes such as hematoxylin (i. e. they are basophilic). This layer is the **granular layer**, or *stratum granulosum* and the granules are called the keratohyaline granules. The cytoplasm of the cells in the stratum corneum is filled with keratin and the entire apparatus for protein synthesis and energy production, i. e. the nucleus, the mitochondria, the endoplasmic reticulum and the Golgi complex, is lost. In a parakeratinised epithelium, however, the cells of the stratum corneum contain remnants of nuclei.

The surface layer is composed of very flat, eosinophilic cells. The layer is the **keratinised layer** or *stratum corneum*. Other names sometimes encountered include *cornified*



**Fig. 5.** Gingival stratified squamous epithelium:

1 — keratinised layer or *stratum corneum*; 2 — granular layer; 3 — prickle-cell layer or *stratum spinosum*; 4 — basal layer; 5 — gingival connective tissue (lamina propria)

## PART I. PERIODONTAL DISEASES

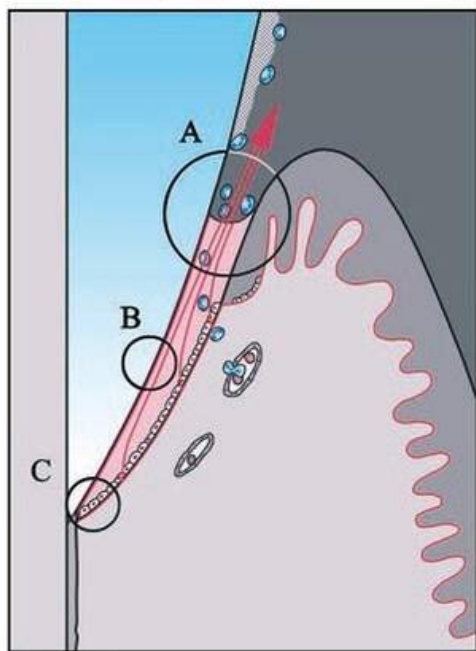
layer and *horny layer*. The pattern of maturation of these cells is often termed orthokeratinisation. Keratinisation is considered a process of differentiation rather than degeneration. It is a process of protein synthesis which requires energy and is dependent on functional cells, i. e. cells containing a nucleus and a normal set of organelles.

In addition to the keratin-producing cells which comprise about 90 % of the total cell population, the oral epithelium contains the following types of cell: melanocytes, Langerhans cells, Merkel's cells, inflammatory cells. These cell types are often stellate and have cytoplasmic extensions of various size and appearance. They are also called *clear cells* since in histologic sections, the zone around their nuclei appears lighter than that in the surrounding keratin-producing cells. The Langerhans cells are believed to play a role in the defense mechanism of the oral mucosa. It has been suggested that the Langerhans cells react with antigens which are in the process of penetrating the epithelium. An early immunologic response is thereby initiated, inhibiting or preventing further antigen penetration of the tissue. Merkel's cells have been suggested to have a sensory function.

Although the gingival epithelium constitutes a continuous lining of stratified squamous epithelium, three different areas can be defined from the morphologic and functional points of view: the oral or outer epithelium, the sulcular epithelium and the junctional epithelium.

**Junctional Epithelium.** The marginal gingiva attaches to the tooth surface by means of the junctional epithelium, an attachment that is continuously being renewed throughout life.

The junctional epithelium (JE) is approximately 1–2 mm in the coronal dimension and surrounds the neck of each tooth. At its apical extent, it consists of only a few cell layers; more coronally, it consists of 15–30 cell layers. Subjacent to the sulcus



**Fig. 6.** Structure of junctional epithelium:

A — gingival sulcus; B — epithelial attachment; C — apical extent of the junctional epithelium

bottom, the junctional epithelium is about 0.15 mm wide. The junctional epithelium consists of two layers, basal (mitotically active) and suprabasal (daughter cells). It remains undifferentiated and does not keratinise (Fig. 6).

The JE assumes a key role in the maintenance of periodontal health: it produces *epithelial attachment* and therefore creates the firm connection of the soft tissue to the tooth surface.

The epithelial attachment to the tooth is formed by the JE and consists of an *internal basal lamina* (IBL) and *hemidesmosomes*. It provides epithelial attachment between the gingiva and the tooth surface. This can be upon enamel, cementum or dentin in the same manner.

**Gingival Sulcus.** The sulcus is a narrow groove surrounding the tooth, about 0.5 mm deep. The bottom of the sulcus is made up of the most coronal cells of the junctional epithelium, which are sloughed (exfoliated) in rapid succession.

The epithelium is joined to the underlying connective tissue by a *basal lamina* 300 to 400 Å thick,

which lies approximately 400 Å beneath the epithelial basal layer. The basal lamina consists of lamina lucida and lamina densa.

**Gingival Connective Tissue.** The predominant tissue component of the gingiva is the connective tissue (lamina propria). The major components of the connective tissue are collagen fibres (around 60 % of the connective tissue volume), fibroblasts (around 5 %), vessels and nerves (around 35 %) which are embedded in an amorphous ground substance (matrix).

The fibrous connective tissue structures provide attachment between the teeth (via cementum) and their osseous alveoli, between the teeth and the gingiva, as well as between each tooth and its neighbour. These structures include gingival fibre groups and periodontal fibre groups (periodontal ligament).

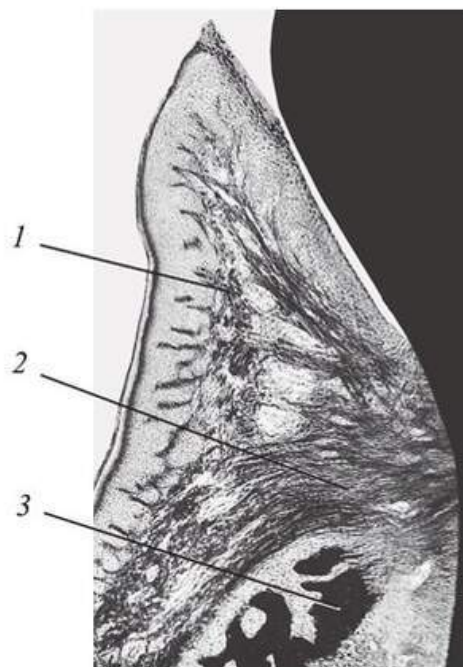
The connective tissue fibres are produced by the fibroblasts and can be divided into: (1) collagen fibres, (2) reticulin fibres, (3) oxytalan fibres and (4) elastic fibres. The collagen fibres predominate in the gingival connective tissue and constitute the most essential components of the periodontium.

The boundary between the gingival epithelium and the underlying connective tissue has a wavy course. The connective tissue portions which project into the epithelium are called connective tissue papillae and are separated from each other by epithelial ridges — so-called rete pegs. In normal, non-inflamed gingiva, rete pegs and connective tissue papillae are lacking at the boundary between the junctional epithelium and its underlying connective tissue. Thus, a characteristic morphologic feature of the oral epithelium and the oral sulcular epithelium is the presence of rete pegs, while these structures are lacking in the junctional epithelium.

In the supra-alveolar area, collagen fibre bundles course in various directions (Fig. 7). These fibres give the gingiva its resiliency and resistance and attach it onto the tooth surface subjacent to the epithelial attachment. The fibres also provide resistance to forces and stabilise the individual teeth into a closed segment. The periosteogingival fibres are also a component of the gingival fibre complex. These connect the attached gingiva to the alveolar process.

The preponderant cellular element in the gingival connective tissue is the *fibroblast*. Numerous fibroblasts are found between the fibre bundles. As in the connective tissue elsewhere in the body, fibroblasts synthesise collagen and elastic fibres, as well as the glycoproteins and glycosaminoglycans of the amorphous intercellular substance. Fibroblasts also regulate collagen degradation.

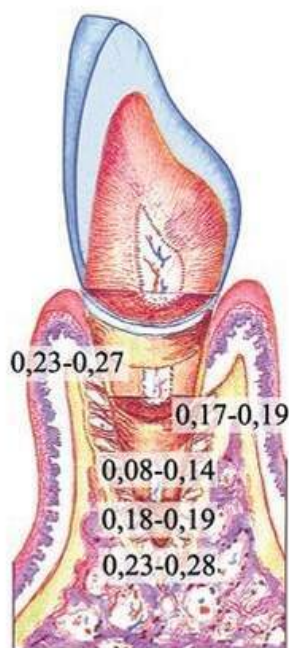
*Mast cells*, which are distributed throughout the body, are numerous in the connective tissue of the oral mucosa and the gingiva. *Fixed macrophages* and *histiocytes* are present in the gingival connective tissue as components of the mononuclear phagocyte system (reticuloendothelial system) and derived from blood monocytes. *Adipose cells* and *eosinophils*, although scarce, are also present in the lamina propria.



**Fig. 7.** Faciolingual section of the marginal gingiva showing gingival fibres:

1 — gingival fibres; 2 — circular fibres; 3 — alveolar bone

## PART I. PERIODONTAL DISEASES



**Fig. 8.** The width of the periodontal ligament

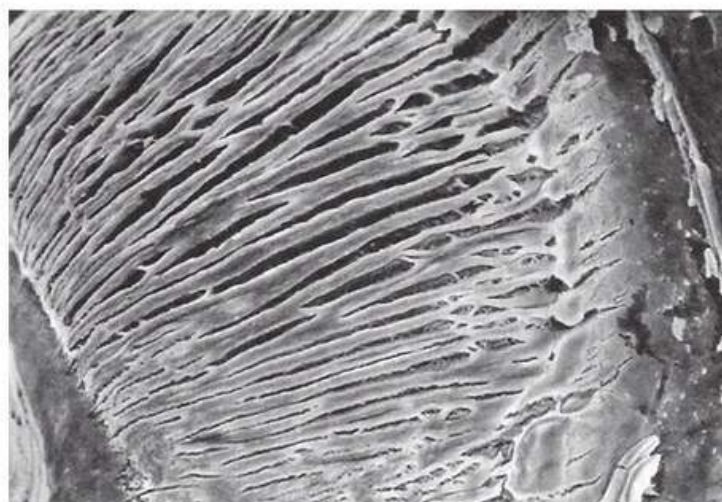In clinically normal gingiva, *small foci of plasma cells and lymphocytes* are found in the connective tissue near the base of the sulcus. Neutrophils can be seen in relatively high numbers in both the gingival connective tissue and the sulcus. These inflammatory cells are usually present in small amounts in the clinically normal gingiva. Their presence is believed to be related to the penetration of antigenic substances from the oral cavity via the sulcular and junctional epithelia.

### Periodontal Ligament

The periodontal ligament (PDL) occupies the space between the root surface and the alveolar bone surface. The periodontal ligament space has the shape of an hourglass and is narrowest at the mid-root level. The width of the periodontal ligament is approximately 0.25 mm (range 0.2–0.4 mm, Fig. 8).

The periodontal ligament consists of connective tissue fibres, cells, vasculature, nerves and ground substance. An average of 28,000 fibre bundles insert into each square millimetre of root cementum!

The building block of a fibre bundle is the 40–70 nm thick collagen fibrils. Many such fibrils in parallel arrangement make up a collagen fibre. Numerous fibres combine to form collagen fibre bundles. These collagen fibre bundles (Sharpey's fibres) insert into the alveolar bone on one end and into cementum at the other (Fig. 9). The most ubiquitous cells are fibroblasts, which appear as spindle-shaped cells with oval nuclei and numerous cytoplasmic processes of varying lengths. These cells are responsible for the synthesis and break-down of collagen ("turnover"). Cells responsible for the hard tissues are the cementoblasts and osteoblasts (Fig. 10). Osteoclastic cells are only observed during phases of active bone resorption. Near the cementum layer, within the periodontal ligament space, one often observes string-like arrangements of epithelial rest cells of Malassez. The periodontal ligament tissues are highly vascularised and innervated.



**Fig. 9.** The periodontal ligament collagen fibre bundles



## Root Cementum

The cementum is a specialised mineralised tissue covering the root surfaces and, occasionally, small portions of the crown of the teeth. It has many features in common with the bone tissue. However, the cementum contains no blood or lymph vessels, has no innervation, does not undergo physiologic resorption or remodelling, but is characterised by continuing deposition throughout life. From a purely anatomic standpoint, the root cementum is part of the tooth, but also part of the periodontium. Four types of cementum have been identified: acellular, afibrillar cementum; acellular, extrinsic-fibre cementum; cellular intrinsic fibre cementum; cellular mixed fibre cementum (Fig. 11).

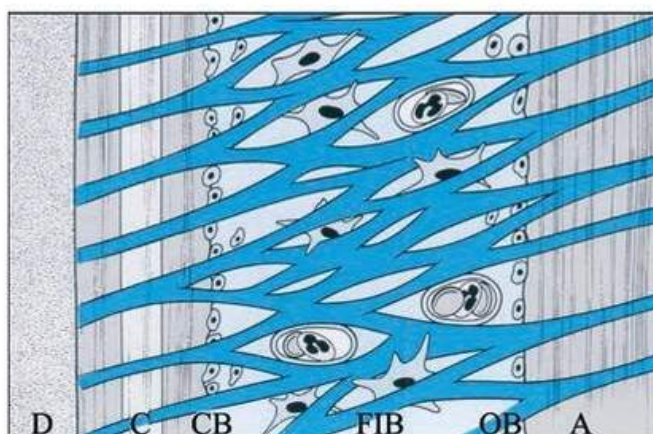
Fibroblasts and cementoblasts collaborate in the formation of cementum. *Periodontal ligament fibroblasts* secrete acellular extrinsic cementum. *Cementoblasts* secrete cellular intrinsic cementum and a portion of the cellular mixed fibre cementum and probably also acellular afibrillar cementum.

## Alveolar Bone

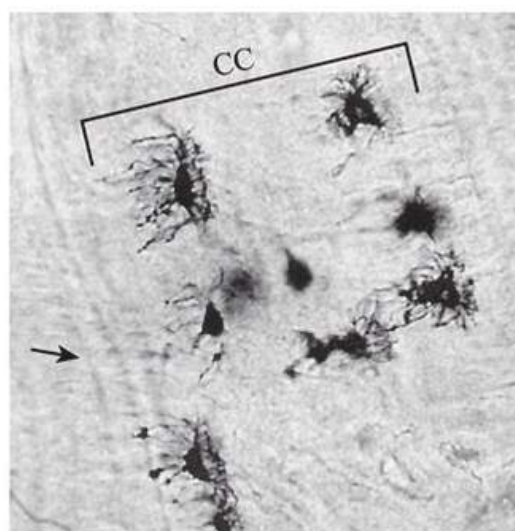
The alveolar bone consists of two components, the alveolar bone proper and the alveolar process. The alveolar bone proper, also called *bundle bone*, is continuous with the alveolar process and forms the thin bone plate that lines the alveolus of the tooth.

The *alveolar processes* of the maxilla and the mandible are tooth-dependent structures. They develop with the formation of and during the eruption of the teeth and they atrophy for the most part after tooth loss. Three structures of the alveolar process may be discriminated: alveolar bone proper, trabecular bone, compact bone (Fig. 12).

The alveolar process consists of (1) an external plate of the cortical bone formed by the haversian bone and compacted bone lamellae; (2) the inner socket wall of the thin, compact bone called the *alveolar bone proper* (also known as the *cribriform plate* or *lamina dura*) and also formed by the bundle bone; and (3) cancellous trabeculae, between these two compact layers, which act as supporting alveolar bone. The *interdental septum* consists of the cancellous supporting bone enclosed within a compact border (Fig. 13).



**Fig. 10.** Periodontal ligament:  
D — dentin; C — cementum; CB — cementoblasts;  
FIB — fibroblasts; OB — odontoblasts; A — alveolar bone



**Fig. 11.** Cellular (CC) and acellular (arrow) cementum

**ridmi**  
ТВІЙ УЛЮБЛЕНИЙ КНИЖКОВИЙ

**КУПИТИ**